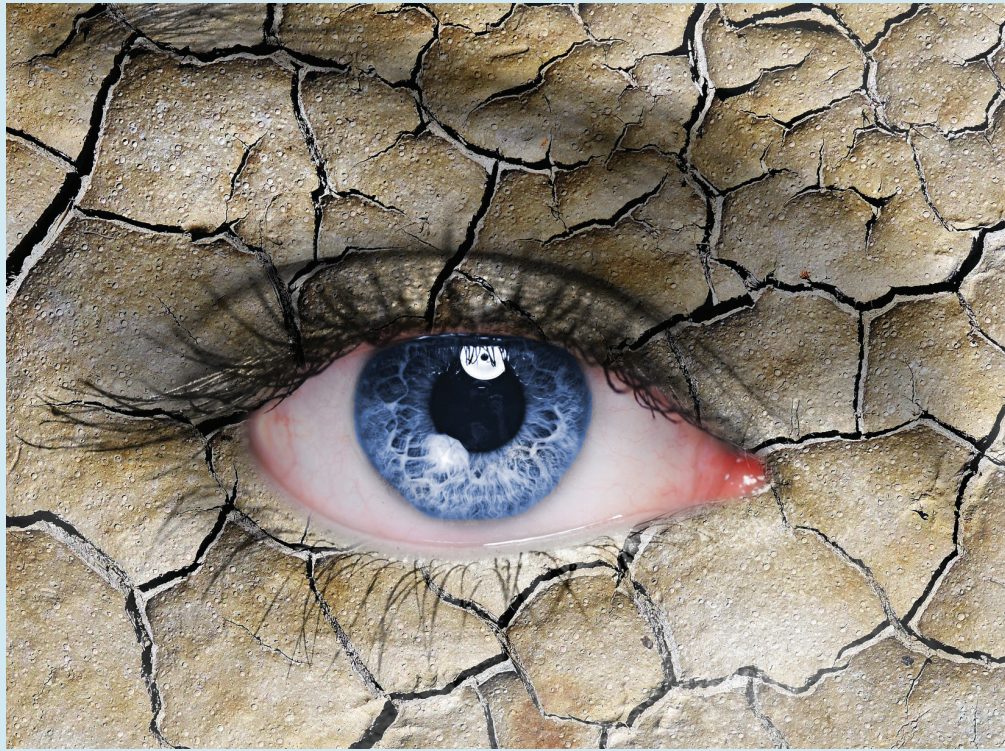

# Dry eye grows up

EDITORIAL BY LESLEY SPRINGALL, EDITOR, NZ OPTICS



Since we first dedicated a special feature to all that's new in dry eye from this part of the world, just two short years ago, the rise in scientific papers, new products and interest in dry eye from all parts of the industry and globally has grown exponentially.

Attempting to put parameters around where we've got to and where we still have to go clinically, to begin making a real difference to dry eye patients' lives, is the Tear Film & Ocular Surface Society (TFOS). This report aims to celebrate TFOS' achievement with the recent publication of its second Dry Eye Workshop (DEWS) report and highlight how this part of the world is continuing to lead the way in many fields relating to dry eye.

NZ Optics would like to thank the authors of

all the contributed articles in this feature. Their stories provide a breadth of understanding about where we're at with dry eye and where we're going. It's a privilege to be able to present these articles.

We would also particularly like to acknowledge and thank New Zealand's own dry eye expert, Associate Professor Jennifer Craig, vice-chair of DEWS II and passionate researcher into all things dry eye, who was instrumental in helping to curate and review the following articles. As well as championing many of the unsung heroes beaver away on dry eye behind the scenes, we both hope the articles presented here build on past features and help enlighten and inform current thinking and stimulate further thought on all that is or could be dry eye.

# TFOS DEWS II and all that's new with dry eye

BY ASSOCIATE PROFESSOR JENNIFER CRAIG\*

Emerging from the buzz of TFOS DEWS II, I'm getting my first chance to step back and take stock of the work that 150 experts in the field have contributed, pro bono, to reach consensus on many aspects of dry eye and deliver a report for use by clinicians, researchers, industry and regulators, to improve patient care and inspire continued advancement of the field. Those close to me have witnessed the magnitude of this undertaking, but now that this impressive body of work is published in the *Ocular Surface* journal, I hope you'll agree that the results speak for themselves. Like previous TFOS workshop reports, access is free to all and the individual reports making up the TFOS DEWS II report can be downloaded from:

The *Ocular Surface*:

<http://www.theocularsurfacejournal.com/>

or TFOS:

[http://www.tearfilm.org/accreports-access\\_tfos\\_dews\\_ii\\_report/126\\_126/eng/](http://www.tearfilm.org/accreports-access_tfos_dews_ii_report/126_126/eng/)

If the thought of a 400-page report remains too daunting, you might be interested to hear that there will be a TFOS DEWS II Executive Summary published (also open access) in the next issue of the *Ocular Surface* journal.

As I mentioned during my interview with NZ Optics (see pX), TFOS DEWS II has been an incredible opportunity to increase global recognition of the New Zealand National Eye



TFOS DEWS II Steering Committee, with A/Prof Jennifer Craig (front row, third, with pendant).

Centre and our Ocular Surface Laboratory (OSL), with researchers around the world showing increasing interest in the research being conducted somewhere that many had previously considered to be close to 'the end of the Earth'.

I'd encourage you to read the short articles in this supplement that give a snapshot of the current research interests of many, although by no means all, of the hardworking team at the OSL. However, I would also like to make mention of the rising number of collaborative projects we have underway in various centres around the world.

Further to Ally Xue's study of dry eye prevalence, diagnosis and treatment in New Zealand, carried out in collaboration with the University of Melbourne, we are extending the study to Canada with TFOS members, Dr Sruthi Srinivasan at the University of Waterloo and A/Prof Etty Bitton at

CONTINUED ON PAGE 8



## 13th Annual Scientific Conference

1/2 day workshops  
Saturday afternoon  
4th November 2017

Optometry Conference  
Sunday 8.00am - 5.00pm  
November 5th 2017

Join us for an exciting new education format  
for Optometrists, Dispensers & Staff

**Venue:** Waipuna Hotel & Conference Centre.  
58 Waipuna Rd, Mt Wellington Auckland

**Book now:** for your 2017/2018 CPD Credits  
(including Therapeutics)

**Registrations:** p +64 9 522 2125 | f +64 9 529 1814  
e [professionaleducation@eyeinstitute.co.nz](mailto:professionaleducation@eyeinstitute.co.nz)

Register online at:  
[eyeinstitute.co.nz/Health-professionals/Events/Upcoming-events](http://eyeinstitute.co.nz/Health-professionals/Events/Upcoming-events)

**Assoc. Prof. Mark Roth is our 2017 International Guest Speaker.** he is a clinical optometrist with a degree in pharmacology, he is currently in private practice and is also a principle fellow in the Department of Optometry & Vision Sciences, Faculty of Medicine & Health Sciences at The University of Melbourne.

He lectures widely at conferences in Australia and overseas and is involved in many optometry therapeutic teaching programs. Assoc. Prof Roth's keynote lecture is "Therapeutic management of contact lens problems".

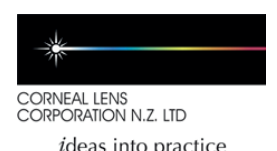

## Thanks to our Conference Sponsors

Gold sponsors



Silver sponsors





CONTINUED FROM PAGE 7

Université de Montréal (where the survey has been translated into French). Our collaborations with Dr Laura Downie at the University of Melbourne continue, with joint supervision of ex-Auckland optometrist, now Melbourne-based PhD student, Ceecee Zhang. Ceecee began her PhD studies looking at the role of essential fatty acids in corneal nerve structure and function earlier this year, and we look forward to welcoming her to the Laboratory in Auckland for research visits during the course of her studies. A longstanding collaboration with Aston University in the UK has strengthened in recent years and we have a number of joint dry eye projects underway, which are expected to expand opportunities for publishing peer-reviewed articles and acquiring international research funding. As well as the global epidemiology study described by Jovey Lim (see pX), current projects include evaluation of the Optrex Blink Test by BOptom

Honours student, Lexia Ahkit, and a survey-based exploration of the natural history of dry eye by fellow Part V student, Kylie Mann. Further joint research initiatives are planned for 2018 with the University of New South Wales and Harvard Medical School in Boston, USA in two studies that will take very different approaches to the study of contemporary dry eye therapies. In the meantime, there's plenty going on at home, too. **Baby shampoo beliefs tackled** Through anecdotal evidence, baby shampoo has been losing favour over the years as an eyelid cleanser, but supportive scientific evidence has been lagging. The OSL decided to address this with a randomised, double-masked clinical trial conducted by BMedSc honours student Justin Sung, with clinical input from optometrist and MSc student Sang Hoo Lee. The study uncovered evidence that further supports the clinical move to diminish reliance on baby shampoo in favour of

dedicated lid cleansers, a finding that has sparked the interest of the College of Optometrists in the UK, as well as local practitioners. **Artificial tear drug delivery?** Evaluating the full potential of novel therapeutic strategies for dry eye provides exciting research opportunities for PhD students. In a project which bridges the research interests of the Buchanan Ocular Therapeutics Unit, also at Auckland University, and the OSL, Priyanka Agarwal, is currently looking at one of the latest topical formulations with potential applications as an artificial tear product and as a vehicle for drug delivery. **IPL and UVC** Ally Xue and Sanjay Marasini are nearing completion of their PhD studies investigating potential mechanisms to explain improved meibomian gland function with intense pulsed light (IPL) therapy and the potential of UVC for

treating microbial keratitis, respectively. We look forward to reporting the results of these projects, along with the Laboratory's other dry eye projects described in this supplement, in due course. There are so many studies underway at the OSL, there are almost always projects actively seeking participants with and without dry eye. So if you're interested in finding out more, or you have patients who might be interested in contributing to our research efforts, please do get in touch and we will do our best to offer a project to suit. If I have learned one thing from TFOS DEWS II, it is that great things can be achieved with the collaborative efforts and dedication of very many people. Let's keep New Zealand on the map by continuing to work towards making a difference for individuals with dry eye! *"A/Prof Jennifer Craig is head of the Ocular Surface Laboratory at the University of Auckland, vice-chair of TFOS Dews II and clinical editor of NZ Optics' annual 'Special feature on dry eye'."*

DEWS II report published

After almost two and a half years of work, the near 400-page TFOS DEWS II report has been published by the Tear Film & Ocular Surface Society (TFOS). This massive undertaking involved 150 researchers from 23 countries who analysed, crunched and compared thousands of evidence-based articles into reports covering all factors relating to dry eye. Building on the work begun in 1995 by the US-based National Eye Institute and the completely ground-breaking TFOS DEWS report in 2007, the DEWS II report aimed to: 

- Update the definition, classification and diagnosis of dry eye disease (DED);
- Critically assess the etiology, mechanism, distribution and impact of the disorder; and
- Address its management and therapy

 This mammoth task was led by a 25-member steering committee, chaired by Dr Dan Nelson, associate medical director for specialty care for HealthPartners Medical Group and Clinics in Minnesota; the vice-chair was New Zealand's own Jennifer Craig, associate professor in the Department of Ophthalmology at the University of Auckland; and the organiser was Dr David Sullivan,

associate professor at Harvard Medical School. Ten sub-committees were created to develop reports to cover definition and classification; sex, gender, and hormones; epidemiology; tear film; pain and sensation; pathophysiology; iatrogenic dry eye; diagnostic methodology; management and therapy; and clinical trial design. There were two additional subcommittees that focused on public awareness and education; and industry liaison. **Definition** The report highlights a number of areas that require further study to better clarify the extent and precise nature of some of the causes and prevalence (especially south of the equator and in younger people) of DED, and to better diagnose dry eye. But the new definition, and clear diagnostic criteria, will help standardise studies so they can be better compared, combined and understood, says A/Prof Craig. The newly developed TFOS DEWS II definition states: **Dry eye is a multifactorial disease of the ocular surface characterised by a loss of homeostasis of the tear film, and accompanied by ocular**

**symptoms, in which tear film instability and hyperosmolarity, ocular surface inflammation and damage, and neurosensory abnormalities play etiological roles.** **Key findings** Other key findings include: 

1. Meibomian gland dysfunction (MGD) and Sjögren and non-Sjögren lacrimal disease remain leading causes of evaporative and aqueous-deficient DED, respectively, but many hybrid forms of DED exist.
2. Evidence supports the more contemporary two-phase model of the tear film, with a lipid layer overlying a mucoaqueous phase. While the whole tear film (lipids, mucins, proteins and salts) may prevent tear film evaporation and collapse, additional studies are needed to confirm this.
3. It's now understood that sex, gender, and hormones play a major role in the regulation of the ocular surface and adnexal tissues, however further studies are needed to clarify the exact nature, extent and mechanisms of their effects
4. Inflammation of the ocular surface can cause inhibition of lacrimal secretion and loss of epithelial barrier function at the ocular surface, thus the role of increased friction in DED needs further investigation.
5. The most prominent nerve disturbance is with cold thermoreceptors, suggesting that dryness-induced nerve damage dominates over inflammation
6. Topical and systemic medications, contact lenses, ophthalmic surgeries and non-surgical procedures can cause DED. Work is needed to better define specific risk factors, create less toxic medications and preservatives, devise less invasive ophthalmic procedures and identify early DED prior to surgery.
7. Currently the best way to diagnose DED involves triaging questions, risk factor analysis and symptoms analysis, combined with a detailed anterior eye exam for further evaluation should



TFOS' imagery to promote the highly-anticipated TFOS DEWS II report

DED be suspected. New approaches and better-validated instrumentation and techniques are needed to more critically assess DED and to link underlying causes in an individual to the most suitable therapies to manage their DED. **8.** Restoration of tear film homeostasis is the ultimate goal in the management of DED, therefore determining whether the major cause of a person's DED pertains predominantly to aqueous tear deficiency or evaporative causes, or both, is critical in helping select the most appropriate management strategy. "The TFOS DEWS II report is available for download at no cost, and I encourage my colleagues to read it," said Bill Townsend, president of the US Ocular Surface Society of Optometry, in *Optometry Times*. "It sheds important light and offers new evidence about on one of the conditions that (optometrists) commonly encounter. Kudos to this distinguished group for their work leading to this publication." In the same *Optometry Times* article, US-based Dr Milton Hom called the TFOS DEWS II report "groundbreaking". "What have I learned? Dry eye is the new multi disease: multi-factorial, multi-coloured, multi-cultural, multi-flavored... I'm absolutely certain TFOS DEWS II will be the new standard to follow. Hats off to TFOS for a great accomplishment." See story on p3 on A/Prof Jennifer Craig's experience of co-managing TFOS DEWS II

Add data to your insights.

There is quantitative data in every eye. Uncovering this information can help guide your diagnosis and management of the ocular surface. In fact, the point-of-care TearLab Diagnostic Test provides precise and predictive information regarding tear osmolarity, an important biomarker of ocular surface health.

To learn more, visit [TearLab.com](http://TearLab.com)



 **TearLab.**


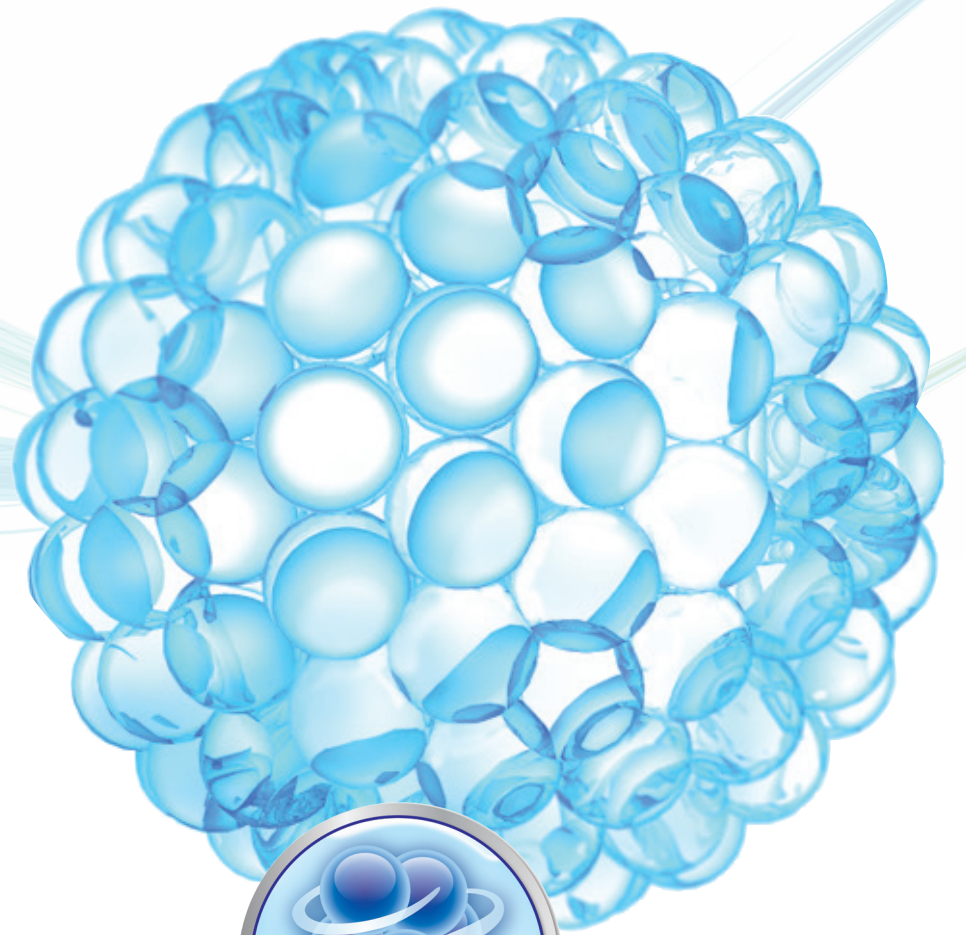
  
phone 09 443 0072 email [tim@oic.co.nz](mailto:tim@oic.co.nz)

Glaucoma meds and DED

By Michael Wang, on behalf of University of Auckland study co-authors Dr Aaron Wong, Dr Zac Prime, Prof Helen Danesh-Meyer and A/Prof Jennifer Craig **G**laucoma and dry eye syndrome are both prevalent chronic conditions, which frequently co-exist in ophthalmic patients. Although the association between the two conditions is not fully understood, the long-term use of topical anti-glaucoma medications is thought to be a contributing factor to dry eye predisposition. Previous studies have shown that preservatives used in ophthalmic formulations are toxic to the corneal epithelium and destabilise the tear film, and long-term use may potentially exacerbate meibomian gland dysfunction. Recently, a cross-sectional paired-eye study was conducted jointly by the Glaucoma and Neuro-ophthalmology Research Unit and the Ocular Surface Laboratory at the University of Auckland to further explore the relationship between anti-glaucoma medications and dry eye disease (DED). The results suggest that in addition to the previously reported predisposition towards meibomian gland dysfunction and evaporative causes, aqueous deficiency and inflammatory mechanisms may also be implicated in the development of dry eye in patients receiving long-term topical anti-glaucoma medications.



# THIS IS WHY you can provide patients with comfort that lasts\*<sup>1</sup>



## EXCELLENT DISINFECTION AND CLEANING<sup>2-4</sup>

providing 99%<sup>‡</sup> antimicrobial efficacy and effective cleaning of deposits<sup>†</sup>



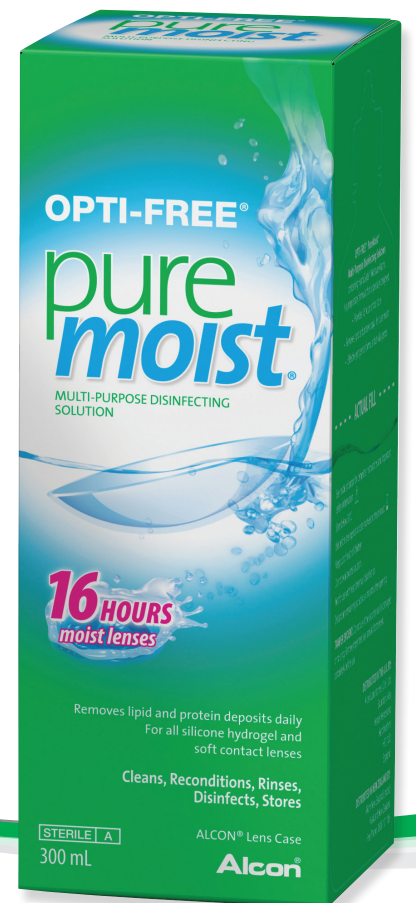## ADVANCED BIOCOMPATIBILITY<sup>5</sup>

demonstrated by minimal corneal staining



## SUPERIOR COMFORT<sup>1,6</sup>

with continuous hydration for up to 16 hours



## PERFORMANCE DRIVEN BY SCIENCE™

ALWAYS READ THE LABEL. USE ONLY AS DIRECTED.

\* Up to 16 hours.

‡ Based on laboratory studies on selected organisms.

† Tested with cholesterol as a model lipid, shown to deposit most on silicone hydrogel lenses.

**References:** 1. Lally J *et al.* A new lens care solution provides moisture and comfort with today's CL's. *Optician* 04/01/2011;241(62960):42-46. 2. Subbaraman L *et al.* In Vitro Efficiency of Contact Lens Care Solutions in Removing Cholesterol Deposits from Silicone Hydrogel Contact Lenses. *Cont Lens Anterior Eye* 2013;36(Suppl 2):e41. 3. Codling CE *et al.* Aspects of the antimicrobial mechanisms of action of a polyquaternium and amidoamine. *J Antimicrob Chemo* 2003;51:1153-58. 4. Kern J *et al.* Antimicrobial properties of a novel contact lens disinfecting solution, OPTI-FREE® EverMoist®. *Cont Lens Anterior Eye* 2011;34(Suppl 1):S30. 5. Andrasko G and Ryen K. Corneal staining and comfort observed with traditional and silicone hydrogel lenses and multipurpose solution combinations. *Optometry* 2008;79(8):444-54. 6. Lemp J and Kern J. Results from a global survey of contact lens-wearer satisfaction with OPTI-FREE® PureMoist® Multi-Purpose Disinfecting Solution. *Clin Optom* 2013;5:39-46.



# Honey for blepharitis?

BY GRANT WATTERS\*

In the 1980s, Professor Peter Molan of Waikato University, having heard Māori legends about the medicinal properties of manuka, established a Honey Research Unit and developed methods to evaluate the antibacterial activity of mānuka honey, a feature that was termed the Unique Manuka Factor (UMF).

Prof Molan and his colleagues isolated high levels of a strongly antibacterial and anti-inflammatory organic compound called methylglyoxal (MGO) which is unique to mānuka honey, and demonstrated its effectiveness in wound healing. Manuka-infused bandages have since become popular and effective in treating burns victims and previously non-healing chronic ulcerations.

In 2012, a collaboration began between Auckland company, Manuka Health, and the University of Auckland's Department of Ophthalmology to investigate potential ocular applications of high UMF mānuka honey. It quickly became apparent that blepharitis, with its underlying chronic bacterial and inflammatory associations, could be considered a target for a manuka honey-based therapy.

With similarities to gut health, ocular surface health requires the ocular surface microbiome to be kept in balance. A well-known trigger for blepharitis is an overpopulation of gram-positive *Staphylococcus spp.*, leading to inflammatory eyelid disease and ocular surface sequelae (see story p10). In the background, Manuka Health had been working on improving the bioavailability of their honey product with the development of a complexed honey-based formulation (Manuka Honey with Cyclopower) which comprised freeze-dried manuka honey solids encased in alpha-cyclodextrin, a type of soluble fibre which allows for a more sustained release of MGO. Independently, this led to the commercialisation of a new Manuka Health oral supplement that offers more effective delivery of the active components of manuka honey to the bacteria resident in the gut.

Over the last five years, our team, working across three Auckland University departments – ophthalmology, molecular medicine and



A tried and tested manuka honey product for blepharitis is close

pathology and optometry – has developed an exciting manuka honey-based eyelid cream for overnight application, in the hope of better managing blepharitis. Extensive in vitro and in vivo studies have been performed to establish the optimal dosage for targeted bactericidal effectiveness, while ocular surface inflammatory modulation, tear film and ocular surface integrity and toxicology have been monitored, to produce a safe and effective formulation which aims to modulate the levels of both gram-positive bacteria and tissue inflammation. Clinical efficacy trials are now in progress and, depending on the outcomes, there's the possibility that we might see this novel and uniquely New Zealand-based treatment for blepharitis, on shelves in our stores in the not too distant future.

*\*Grant Watters is an optometrist, specialising in complex contact lens fitting and management, orthokeratology and keratoconus, and a lecturer and researcher with Auckland University*

# Osmolarity: the “gold standard”

This objective point-of-care test offers strong predictive value for diagnosis of dry eye disease. By Dr Marc Bloomenstein\*

Osmolarity is my number one test for dry eye. I view it as the “standard of care” because it presents an evaluation of the properties of a patient's tears and offers a strong predictive tool for dry eye diagnosis, in contrast to other less effective dry eye point-of-care tests.

The Schirmer's test, for example, is limited from the perspective that all it does is give us a volume of tears coming out of the eye, with no information about the quality or properties of those tears. Few doctors perform the test because it is not very predictive. For a patient with aqueous deficiency or an underlying systemic disease such as Sjogren's syndrome, a Schirmer's test could be beneficial in confirming if the lacrimal gland has any capacity to reflex tear. However, we know that dry eye disease is multifactorial, so such an invasive measure of tear volume limits our ability to understand what is going on.

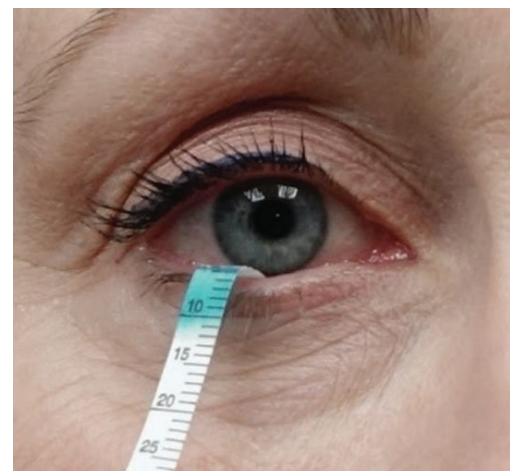Tear break-up time (TBUT) is somewhat informative, but it is not very precise and does not have a strong predictive value. If I know that my patient's tears are breaking up, I do not know the severity or underlying cause of the problem. In addition, although low TBUT implies a problem, patients with poor tear quality can sometimes appear to have a high TBUT.

Some doctors test for the inflammatory marker MMP-9 (InflammaDry, Quidel), but I have opted not to use that test. The inflammatory nature of dry eye disease means that if there is an increase in osmolarity, then inflammation is also likely. Conversely, because inflammation is not exclusive to dry eye, a positive test may not indicate dry eye. Tear osmolarity offers a higher level of diagnostic specificity.

## Testing tear osmolarity

When a patient comes in complaining of dry eye symptoms, obviously, we start looking for clinical evidence of dry eye. However, in screening all patients for dry eye, I think it is a mistake to begin with redness and discomfort. One of the best metrics for early dry eye disease is fluctuating vision, which is one of the first signs of a decrease or change in tear quality. I ask patients if their eyes get watery and if they can see better if they blink.

Rather than relating vision problems to dryness or irritation, I check the tear osmolarity using TearLab's Osmolarity System\*. If the osmolarity is above 308 mOsm/L or there is an inter-eye difference over 8 mOsm/L, then I know the patient may have dry eye disease, whether or not symptoms are present. This is a call-to-action to do something now, before the patient becomes symptomatic and uncomfortable, especially if the patient is a contact lens wearer. The patient may have allergies, lid structure problems, or other pathologies. When osmolarity is normal, I look for other causes of discomfort or vision changes.



Schirmer's test, no longer considered useful for diagnosing dry eye

## Ease of use

Testing tear osmolarity does not require any special skill or long-term training. In my practice, we use the TearLab system rather than the small handheld device, i-Pen, which is more invasive and has been proven less effective. Anyone in my practice can use the device. We just hover along the lid margin for a few seconds, where it absorbs tears, and then it gives us a value in less than 10 seconds. We actually have the results in the pre-testing room before we move on to the next test. There could be some reflex tearing if you accidentally rubbed the device on the eye, but with practice that's easy to avoid.

As long as patients are advised not to use any eye drops for two hours prior to testing and there has been no dilation, anesthesia or staining, we can do osmolarity testing at any time. If a patient requires an artificial tear to get accurate topography or auto refraction, it is a good idea to pause briefly and check tear osmolarity first because there may be a problem.

With such a fast, simple test at my fingertips, dry eye diagnostic testing is commonplace at my practice. I can diagnose dry eye more accurately for more patients, which in turn pushes me to begin treatment earlier – often even before patients experience symptoms of discomfort. And with early treatment of dry eye, patients are more successful in controlling the disease.

## References

1. Nolfi J, Caffery B. Randomized comparison of in vivo performance of two point-of-care tear film osmometers. Clin Ophthalmol. 2017 May 22;11:945-950.



*"Dr Marc R. Bloomenstein from the Schwartz Laser Eye Centre in Arizona is an adjunct assistant professor with the Arizona and Southern California Colleges of Optometry and on the Clinical Advisory Board of Tear Lab Corp. He's also a popular and amusing international speaker, who first shared his views on osmolarity at the 2017 CCLS conference in Nelson*

# The Asian eye and dry eye

STUDIES BY JI SOO KIM AND ALICIA HAN, UNIVERSITY OF AUCKLAND

A higher prevalence and severity of dry eye, related to meibomian gland dysfunction (MGD), has been reported in Asian populations than in Caucasian populations. However, environmental and methodological differences between studies conducted in different parts of the world make direct comparison of study outcomes challenging.

A previous cross-sectional study published in 2016 by the Ocular Surface research group at the University of Auckland attempted to address this issue by comparing the eyes of New Zealand-born individuals of Asian and Caucasian descent, in whom lifetime environmental exposures might be more similar. The study of 74 individuals, with a mean age of  $22 \pm 3$  years, was the first to show significant differences in the meibomian gland status of Asian and Caucasian eyes. Asian eyes exhibited more meibomian gland drop out. Blink quality also differed between the groups, with the Asian group demonstrating more incomplete blinking than the Caucasian group, although, interestingly, symptom levels did not differ significantly between groups.


It was hypothesised that failure to fully close the eyes during blinking might be leading to decreased meibum (tear film oil) release, and eventually to meibomian gland atrophy. It was also suggested that the Asian eye might be disproportionately predisposed to the development of MGD signs and symptoms in older age. We still don't know,



A higher prevalence of dry eye is reported in Asia


however, how early in life these apparent ethnic differences become clinically detectable.



To help find out, Ji Soo Kim, who has taken a year away from her medical degree to complete a BMedSc Honours with the Ocular Surface research team, is currently investigating whether ethnic differences in the ocular surface exist from childhood, by conducting a cross-sectional study of New Zealand-born Asian and Caucasian children aged 6 – 18. To complete the picture, Part V BOptom student, Alicia Han, is currently recruiting participants to explore differences in signs and symptoms of MGD, between Asian and Caucasian eyes in the older population.







# OPHTHALMIC

..... DIAGNOSTIC SOLUTIONS .....





For further information regarding these leading-edge products please contact Device Technologies Customer Service:

P: 0508 338 423

customers@device.co.nz | www.device.co.nz



# SOME SURFACES ARE WORTH PROTECTING

## THE OCULAR SURFACE IS ONE.

The SYSTANE® innovative portfolio Protects,  
Preserves and Promotes a Healthy Ocular Surface<sup>1-5</sup>

					
<b>RELIEF</b>	<b>HYDRATE</b>	<b>RESTORE</b>	<b>PROTECT</b>	<b>CLEANSE</b>	<b>CLEANSE</b>
<b>SYSTANE® ULTRA</b> Lubricating Eye Drops For dry eye patients with aqueous and mucin layer deficiency <sup>3</sup>	<b>SYSTANE® HYDRATION UD</b> Lubricant Eye Drops For increased hydration and lubrication that allows restoration of damaged cells <sup>6</sup>	<b>SYSTANE® BALANCE</b> Lubricant Eye Drops For dry eye patients with lipid layer deficiency (MGD) <sup>1,7</sup>	<b>SYSTANE® GEL DROPS</b> Lubricant Eye Gel For dry eye patients who need extra protection	<b>SYSTANE® EYE WASH</b> Eye Rinse Solution Gentle cleansing for irritated eyes	<b>SYSTANE® LID WIPES</b> Eyelid Cleansing Wipes For daily lid hygiene
<b>EVERYDAY</b> LESS SEVERITY			<b>PREMIUM</b> GREATER SEVERITY	<b>CLEANSE</b> IRRITATED EYES	<b>CLEANSE</b> DAILY HYGIENE

Recommend **Systane®** and support your patients' ocular surface health.  
Family of Products

<sup>†</sup>meibomian gland dysfunction

FOR HEALTHCARE PROFESSIONALS: ALWAYS READ THE PRODUCT INFORMATION AND RECOMMEND AS DIRECTED.  
ALWAYS READ THE LABEL. USE ONLY AS DIRECTED. IF SYMPTOMS PERSIST, SEE YOUR HEALTHCARE PROFESSIONAL.

References: 1. Christensen M, Blackie CA, Korb DR, et al. An evaluation of the performance of a novel lubricant eye drop. Poster D692 presented at: The Association for Research in Vision and Ophthalmology Annual Meeting; May 2-6, 2010; Fort Lauderdale, FL. 2. Christensen M, Martin A, Meadows D. An Evaluation of the Efficacy and Patient Acceptance of a New Lubricant Eye Gel. Presented at American Academy of Optometry 2011, Boston, MA. 3. Davitt WF, Bloomstein M, Christensen M, et al. Efficacy in patients with dry eye after treatment with a new lubricant eye drop formulation. J Ocul Pharmacol Ther. 2010;26(4):347-353. 4. Aguilar A. Efficacy of a Novel Lubricant Eye Drops in Reducing Squamous Metaplasia in Dry Eye Subjects. Presented at the 29th Pan-American Congress of Ophthalmology in Buenos Aires, Argentina, July 7-9, 2011. 5. Geerling G, et al. The International Workshop on Meibomian Gland Dysfunction: Report of the Subcommittee on Management and Treatment of Meibomian Gland Dysfunction. IOVS. 2011;52(4):2050-2064. 6. Rangarajan, R., et al. (2015) Effects of a Hyaluronic Acid/Hydroxypropyl Guar Artificial Tear Solution on Protection, Recovery, and Lubricity in Models of Corneal Epithelium. J Ocul Pharmacol Ther. 31 (8). p. 491-497. 7. Lemp MA et al. The definition and classification of dry eye disease: Report of the Definition and Classification Subcommittee of the International Dry Eye WorkShop (2007). Ocul Surf. 2007;5:75-92. Alcon Laboratories (Australia) Pty Ltd. Phone: 1800 224 153; NZ: Pharmaco (NZ) Ltd. Auckland. Phone: 0800 101 106. TAPS.PP9344. AU-1012 Feb 2017. © 2017 Novartis

 **NOVARTIS**



# New non-contact corneal device, new study

Kiwi ophthalmologist, *Dr Simon Dean\** has taken a novel approach to designing a state-of-the-art, non-contact corneal aesthesiometer (NCCA). Here he shares his thoughts on the device and its use in a new study investigating cold-sensitive nerve fibre pathways in ocular surface health and disease.

Corneal innervation is an interesting and somewhat complicated research area as not all neural pathways are fully understood. What is known is that there is more than one type of sensory nerve supplying the cornea and they appear to have different roles. Cold thermoreceptors (about 10% of corneal nerves), for example, not only detect cold but also wetness, and are thought to be sensitive to osmolarity as well – as tears evaporate they leave the salts behind, increasing osmolarity and resulting in discomfort. Therefore, their role in regulating basal tear production can be affected by pathological states such as dry eye where hyperosmolarity causes inflammation and damages the nerve endings.

It is well known that HSV keratitis causes decreased corneal sensation and an anaesthetic cornea can succumb to ulceration in neurotrophic keratitis due to interruption of normal tear production and inadequate corneal wetting. Measuring the threshold of corneal sensitivity as objectively as possible is thus important and so it is valuable to have a tool to evaluate the normal and pathological ocular surface environment. While pain is subjective and can be scored quantitatively with a validated questionnaire, the status of corneal nerves can be observed with in vivo confocal microscopy and quantified by aesthesiometry.


Measuring corneal sensitivity objectively (by aesthesiometry) can be useful in a range of pathologies where corneal sensitivity may be altered. Traditionally, corneal sensitivity has been measured using a contact method, but this risks discomfort for the patient and damage to the, sometimes fragile, corneal epithelium. The earliest corneal sensitivity measuring tools were made

of horsehair, which early eye health practitioners used to stimulate sensation from the patient's cornea. Today the most common sensitivity tool is the handheld Cochet-Bonnet aesthesiometer. This uses a thin, retractable, nylon monofilament of constant diameter and variable length that extends up to 6cm. The length is progressively reduced, increasing the force required to bend, until the subject reports sensing the nylon.

The new non-contact corneal aesthesiometer is less invasive than the traditional contact method and also reduces the risk of transferring infection to the patient. It uses a gentle 0.9 second puff of air, the pressure of which can be increased incrementally until the patient detects the puff and reports some sensation. The air puff emerges from a 0.5mm diameter nozzle, 1 cm from the target and can be varied from 0.1 to about 20 millibars in pressure. The device can be used to test the sensitivity not only of the cornea, but of the conjunctiva, as well, including the tarsal (lid) conjunctiva, adjacent to the eyelid margin.

We have found normal corneal sensitivity falls in the range of 0.5 to 0.7 mbar. The device has a camera at the nozzle tip and a built-in video monitor to allow accurate alignment of the air puff tip. The latest version also has a wireless remote control to trigger the puff. Additionally, the air is able to be cooled, which may stimulate different nerve pathways thereby adding another dimension to investigations of corneal innervation in health and disease.

Corneal sensation generally reduces with increasing age and is affected by many different pathologies including multiple sclerosis, cerebrovascular events, herpes zoster ophthalmicus, cocaine abuse, leprosy and



Inside the new, non-contact corneal aesthesiometer

tumours. Dry eye or tear film instability can also alter corneal sensation, with increased sensitivity sometimes resulting in excessive tear production in intermittent bursts with intervening episodes of stinging and burning sensations.

So in dry eye studies where reported discomfort is a common outcome measure, it is useful to be able to measure corneal sensitivity objectively as this helps to minimise the variability associated with patient reported outcomes. So I'm pleased to

report that the new NCCA is being used in a joint New Zealand-Australia study being conducted by my partner Associate Professor Jennifer Craig from The University of Auckland and Dr Laura Downie from The University of Melbourne. The study is designed to investigate variations in corneal sensitivity with temperature and to further investigate thermally sensitive pathways to improve understanding of tear film homeostasis with a view to enabling eye care practitioners to better diagnose and manage dry eye disease.

## When is dry eye not dry eye?

BY DR SIMON DEAN\*

Interestingly pain perceived as ocular surface pain, can differ in origin. Nociceptive pain (caused by a corneal abrasion for example) is the normal activation of the cornea's nociceptors. The majority of nerve endings in the cornea are polymodal nociceptors, which are sensitive to a range of stimuli, including force, noxious chemicals, and heat. These are the nerves that a conventional aesthesiometer would be testing. A minority of nerves, the cold thermoreceptors, are believed to play more of a role in regulating basal tear production and therefore are of interest in dry eye research, which is why the new non-contact corneal aesthesiometer (NCCA) device incorporates a cooling mode to preferentially stimulate these nerves.

Neuropathic pain, on the other hand (for example, post-herpetic neuralgia following shingles) is due to a lesion or disease process in the somatosensory nervous system, and is described as pain without biological value. It has become increasingly well understood, from research in recent years, that damage to corneal nociceptors from tear film instability in dry eye disease, can be responsible for, not only exacerbating dry eye through reduced corneal

sensitivity, but conversely, resulting in a central increase in gain or amplification of the signals from the cornea to compensate. In around 5% of cases, this can explain the increased subjective pain experienced by a small but challenging group of individuals who report symptoms of dry eye that are seemingly out of proportion to their clinical signs. In cases like this, referral of the patient might be indicated as management may best be provided by a pain specialist.

Measuring corneal sensitivity, and attempting to differentiate between the different nerve endings present and the pathways they represent, by using both normal and cold stimuli is proving to be an interesting research area for many clinician scientists, not least because of the new challenges required to design and build new tools, such as the NCCA, which can do the research!



*"Dr Simon Dean is a specialist cataract and refractive surgeon at the Manukau Superclinic and the Eye Institute in Auckland. He is active in teaching and research, is a well-known speaker and has designed and built several ophthalmic instruments, including a corneal collagen crosslinking device and, now, the new NCCA."*

## Understanding DED better in NZ, the world

STUDY BY JOEY LIM, UNIVERSITY OF AUCKLAND

With recognition of the significant burden of dry eye disease (DED) on the healthcare system and in terms of quality of life, understanding DED development in relation to age and ethnicity is critical to exploring avenues for disease prevention and improving current DED management.

To date such risk factor analysis has been hampered by differences in DED classification and diagnostic criteria, as well as varying environmental conditions, internationally, between studies. The unique New Zealand population presents an opportunity to evaluate DED development with age and ethnicity using a standardised protocol, in a population exposed to more similar environmental conditions than might be found globally.

Joey Lim is a medical student who is completing a BMedSc Honours degree between the 5th and

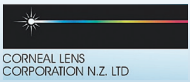6th years of her medical degree. The aim of her study is to evaluate the prevalence and associated risk factors for development of both evaporative and aqueous deficient DED in the New Zealand population with a particular focus on age and ethnicity. As part of her Honours degree, Part V BOptom student, Brinda Mamidi, is also involved in this study, focusing on DED prevalence in Māori and Pacific populations, using the same protocol.

Preliminary results support findings from previous studies that describe increasing DED prevalence with age and a higher DED prevalence in Asian compared with Caucasian populations. The outcomes of these new studies, together with those from Auckland University colleague, Leslie Tien's BOptom honours project conducted last year, will ultimately contribute to the large-scale global epidemiological study being undertaken collaboratively with Aston University in the UK.

## For Longer Dry-Eye Relief Try Thera Tears



For further information call 0800 954 536 or email whitney@corneal-lens.co.nz





# Assessing advances in dry eye technology

BY DR MARIA MARKOULLI\*

Research in dry eye disease has gained momentum – in part due to the recent publication of the Tear Film and Ocular Surface Dry Eye Workshop II (TFOS DEWSII) report, a culmination of more than two years of hard work under the auspices of Dr Dan Nelson and A/Prof Jennifer Craig – and in part due to the acceleration in technology available in this area. At UNSW in Sydney we have been fortunate to be able to work with two such pieces of technology: the Lipiview interferometer (TearScience Inc, Morrisville, NC, USA) and the Oculus Keratograph 5M (Oculus, Arlington, WA, USA). Prior to using these instruments, we studied their repeatability in order to establish their clinical utility and subsequently conducted a study evaluating the impact of ocular lubricants on the variables measured by these instruments.

The Lipiview measures lipid layer thickness objectively by transforming the colour interference patterns produced into quantifiable interferometric colour units. The Oculus, among other things, measures non-invasive break-up time (NIBUT), also objectively, by projecting 22 ring mires onto the cornea. The NIBUT is taken as the time between the last blink and the first distortion detected in the grid images by the computer software. We compared

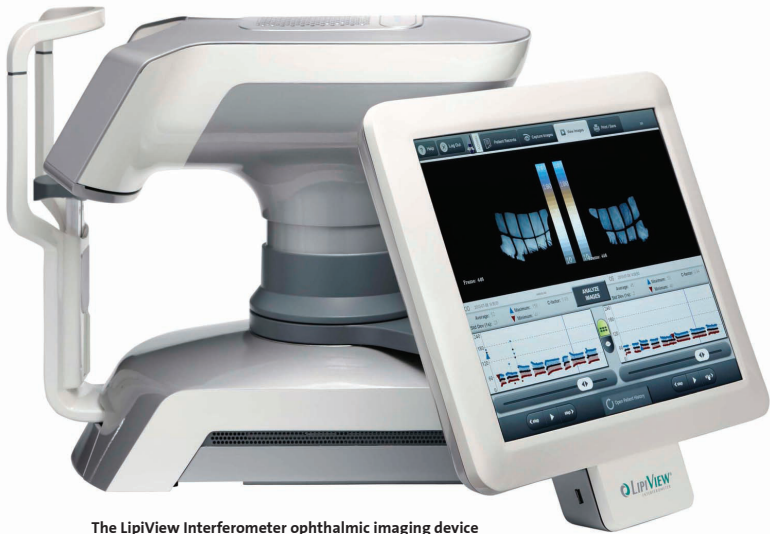these instruments to the Keeler Tearscope-Plus (Keeler, Windsor, UK), a hand-held interferometer used in conjunction with a slit-lamp biomicroscope, that enables both NIBUT and lipid layer thickness to be measured non-invasively, but subjectively. We found the Tearscope to be the most variable of the instruments when it came to measuring NIBUT and assessing lipid layer thickness. Moreover, the Tearscope NIBUT values were significantly higher than those found with the Oculus, and the lipid layer thicknesses were high compared to the Lipiview. We also found that the Lipiview lipid layer thickness was positively correlated with comfort, suggesting it may be of value as a biomarker for dry eye disease.

The Lipiview and the Oculus were subsequently used to determine the impact of lubricants on lipid layer thickness and NIBUT. Twenty participants attended three visits, receiving one of three drops at each visit. The drops given were Optive (Allergan, Irvine, CA), Optive Advanced (Allergan, Irvine, CA) or saline and they were monitored before drop instillation and 5, 15 and 60 minutes after drop instillation. Optive drops are an aqueous-based tear film supplement consisting of carboxymethylcellulose sodium, while Optive Advanced is a lipid-based tear film supplement consisting of the same components as Optive with the addition of polysorbate-80 (0.5%) – designed

to deliver castor oil to the tear film.

We found that Optive Advanced significantly increased lipid layer thickness for the first 15 minutes following instillation and that, by the one-hour point, lipid layer thickness had returned to baseline thicknesses. The other two drops did not change lipid layer thickness during the observed period. Despite the improved lipid layer thickness with Optive Advanced, this did not translate to an improvement in NIBUT for any of the drops observed, suggesting that their effect on dry eye may be via another mechanism, such as osmoprotection. Our results suggest that more regular dosing is required to achieve a longer residence of Optive Advanced in the tear film.

With more advances in the technology available to assess dry eye disease, we will be able to better understand the disease and the efficacy of treatments available.



The LipiView Interferometer ophthalmic imaging device



*"Dr Maria Markoulli is an optometrist, lecturer and researcher with the School of Optometry and Vision Science at the University of New South Wales in Australia. Her research interests include tear film biochemistry and the ocular surface, corneal dystrophies, dry eye disease and contact lens research and development."*

## NZ and True Tear

BY DR DEAN CORBETT\*

I was first introduced to what was to become the TrueTear Nasal Stimulator by its inventor at a meeting at Auckland Eye in 2013. Myself, Michael Ackerman, along with a medical advisor and investor met to discuss possible surgical treatment for dry eye.

The initial concept proposed by Michael Ackerman was that of a surgically implantable device made of gold and titanium, placed adjacent to the lacrimal gland using a relatively minor surgical technique. The plan was to produce a current in the device by holding an external magnetic "switch" close to the temple where the lacrimal gland sits anatomically.

Whilst this attracted some interest, it wasn't until the events that transpired at a particularly momentous lunch at a Mexican restaurant, that things really moved forwards. After ordering particularly hot burrito and taco meals liberally coated in jalapeno peppers, the ensuing deluge of lacrimal gland-derived aqueous tears, as the inventors were eating their spicy food, resulted in that eureka moment – the naso-lacrimal reflex arc could be used for tear stimulation!

Following this intellectual pearl, the inventors looked at different anatomical locations in the nasopharynx and methods of stimulation to optimise tear production via the nasolacrimal reflex. The final site of choice was the nasal septum, and a dual pronged electrical stimulation prototype was born.

This evolved into a product that was initially conceptualised as a device implant in an external treatment application. The implications of this, especially with regard to ease of use and ethical approval, immediately attracted considerable interest from investors, catapulting the project to the investigational level. Despite a number of the team already having undergone implantation of the surgical device above, this avenue is now destined to remain dormant.

My first physical contact with the nasal stimulator prototype was at the Royal Australia and New Zealand College of Ophthalmology (RANZCO) meeting in Hobart in 2013 where, along with a number of Australasian ophthalmologists, I was able to experience the device first hand. Insertion of the prototype device probe up my ample nasal cavity coupled with electrical current delivered via a standard TENS device resulted in a truly eye-watering experience!

Suffering myself from post LASIK dry eye, I was immediately optimistic. Tear supplements often failed to impress, either through effect or issues related to compliance, but now we suddenly had a tool that could induce real, natural tears – what could be better? Severe aqueous deficient dry eye is a condition uncommonly encountered, but patients with this unfortunate affliction are some of the most miserable to be found, with chronic debilitating eye discomfort and terrible impairment of vision.

A multicentre Australasian trial was set up across a number of sites, including Auckland Eye and Eye Institute in Auckland, in collaboration with the Ocular Surface Laboratory at the University, and in Rotorua and Christchurch. Given my enthusiasm, we were lucky enough to enrol the most patients of any individual site in the Australasian arm of the trial. Not surprisingly, however, the concept did draw some raised eyebrows from a number of my colleagues – the idea of



Michael Ackerman PhD, originator of True Tear



Ackerman's initial concept, eventually abandoned in favour of True Tear

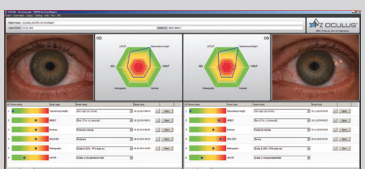
## DRY EYE

## ANALYSIS

### Oculus Keratograph 5M

#### Diagnostic Dry Eye Assessment

Meibo-scan	Imaging	TF-Scan	TF-Scan, R-scan
Infra Red LED	Blue & White LED	White LED	White or IR Placido-ring



With the Jenvis dry eye report, you can easily identify your patients DED origins, and tailor your treatment regime to their needs.



## DRY EYE

## TREATMENT

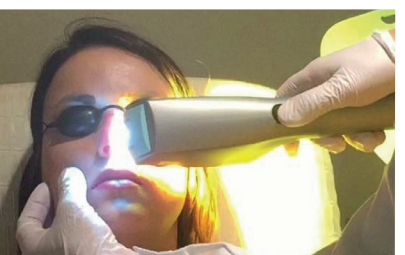### EYE-LIGHT®

#### OPE®/IPL + Light Modulation®/LLLT

- IPL for treatment of the Lower Lid
- LLLT for direct treatment of the Upper lid and face
- No GEL, No mess, streamlined treatment times
- Skin Type detected automatically, no guess work using a grading card
- Pulse intensity is controlled automatically, but can be overridden by experienced operator
- Minimal ongoing costs, unit is often paid for before purchasing replacements

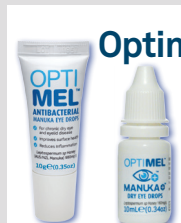Both technologies are certified with FDA and CE Medical Certification.

## IPL, No GEL!



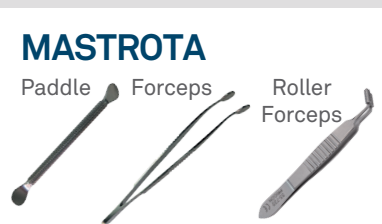### Blephasteam

Therapeutic heat and moisture treatment for the relief of Meibomian Gland Dysfunction and associated diseases.



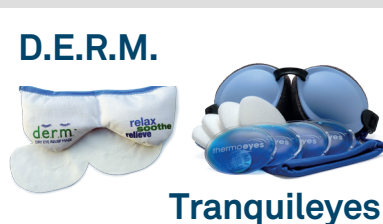### Optimel / Optimel Manuka Plus

Antibacterial Honey Eye Drops for improved ocular surface health and reduced inflammation. Available in a 16% honey drop and 98% honey gel.



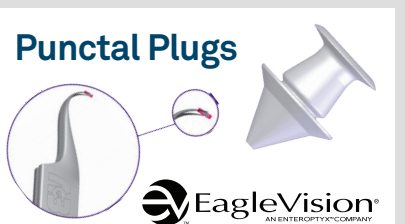
### MASTROTA

Paddle Forceps Roller Forceps



### D.E.R.M.

Tranquileyes



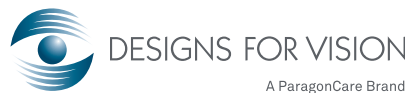### Punctal Plugs

EagleVision

DV891-0817

0800 338 800  
designsforvision.co.nz

Mobile: 021 990 200  
Email: Ralph.Thompson@dfv.com.au



CONTINUED ON PAGE 14



CONTINUED FROM PAGE 13

placing a device up one’s nostrils, met with significant scepticism, but the end result speaks for itself.

The prospective, double-masked trial was very well designed with 50% of patients receiving sham devices. Patients in the placebo arm of the trial were understandably disappointed with its lack of effect, whereas many of those with the active product were delighted.

Happily, in the crossover phase of the trial, those initially receiving sham treatment were offered active devices and the opportunity to benefit from the new treatment. Such was the level of perceived success that when it became time to return the devices (necessary for the trial design and ethics requirements) some patients inexplicably could not find their devices to return!

The device at the time was known as the Oculeve Nasal Stimulator. Since rebranding, following the purchase of Oculeve by Allergan (see associated story p16, it is now known as the TrueTear Intranasal Tear Neurostimulator. The device was cleared by the US Food & Drug Administration earlier this year, with an approved indication for providing a temporary increase in tear production in adult patients.

On attending the Ophthalmology Innovations Summit this year in Los Angeles, I heard Bill Link of Versant Ventures and Bill Saunders from Allergan (among others) pay tribute to Michael, who was honored at the meeting by receiving the prestigious Innovator of the Year award. Michael continues to work with the development team at Allergan today, and apparently has some other new technologies he’s pursuing.

*\*Dr Dean Corbett is a specialist in refractive and glaucoma surgery and a clinical lecturer and a passionate supporter of new devices and surgical techniques for the improvement of vision. He’s based in Auckland at Greenlane Hospital and Auckland Eye.*



Allergan's True Tear device today

# Blepharitis and dry eye, chicken or the egg?

BY LACHLAN SCOTT-HOY\*

For many years, blepharitis and dry eye disease (DED) have been thought to be two distinct diseases, and evaporative dry eye distinct from aqueous insufficiency.

Consider the “chicken-and-egg”, a metaphoric adjective describing situations where it is not clear which of two events should be considered the cause and which should be considered the effect. As eyecare practitioners we tend to focus on the immediate presenting problem and not what preceded it. The two conditions, DED and blepharitis have multiple overlapping symptoms and pathologies intertwined. With a re-evaluation of the existing evidence and intuitive reasoning, is non-Sjogren’s DED simply the late form and late manifestation of one disease, blepharitis?

DED is often the natural sequelae of decades of chronic blepharitis. In 1946, Phillip Thygeson, MD, described blepharitis as, “a chronic inflammation of the lid border”. In spite of the very nature of the word blepharitis (blepha = lid, ritis = inflammation), inflammatory lid disease lacking lash and lid debris would often lead practitioners away from the diagnosis of blepharitis, as if having “scurf” was a prerequisite for having the disease. While terms such as anterior or posterior blepharitis, staphylococcal blepharitis or seborrheic blepharitis as distinctions are rarely isolated, often overlapping and do not serve to accurately describe the stage or duration of disease<sup>1</sup>.

Normal lid margin flora bacteria, primarily *Staphylococcus aureus* and *Staphylococcal epidermidis*, overcolonise the lid margin within a structure known as a biofilm, the most basic of bacterial survival strategies<sup>2</sup>. The eyelid is the perfect environment as biofilms form wherever there is the combination of moisture, nutrients and a surface<sup>3</sup>. Biofilms create a nutritious food supply for the ubiquitous

Demodex mite in the form of a polysaccharide and endogenous bacteria<sup>4</sup>. The biofilm and Demodex mites never go away; the biofilm thickening, and Demodex population increasing with age, producing increasing quantities of bacterial virulence factors, chemokine release and thus, increasing inflammation.

Belonging to the arachnoid species, Demodex mites live in the base of the eyelash follicles and meibomian glands. Lacking an anus, Demodex mites store their faeces internally in a crystallised form until they decompose, releasing their internal contents onto the host eyelid margin<sup>4</sup>. The combination of the biofilm bacterial virulence factors, and large numbers of dying Demodex mites creates a domino effect, first follicular inflammation, then meibomian gland dysfunction, lid wiper epitheliopathy, aqueous insufficiency through inflammatory damage to the accessory lacrimal glands of Wolfring and Krause, destruction of the eyelid anatomy, and ultimately ocular surface disease.

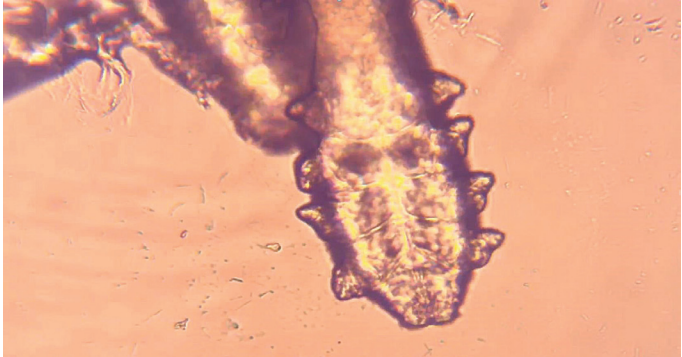


Fig 1. Demodex folliculorum on an epilated eyelash

Antonie van Leeuwenhoek made the first known microscopic observation of a biofilm in 1684; oral bacteria within the scurf of a man’s teeth<sup>5</sup>. Over 100 years ago, no one brushed their teeth or practiced any form of regular oral hygiene, chronic gingivitis preceded eventual tooth loss and dentures were the norm. Dentistry has effectively educated the world on regular and routine oral hygiene and we visit their practices for regular cleaning with the dental hygienist to remove biofilms from our teeth and gums.

With nearly 337 million people suffering from dry eye syndrome worldwide<sup>6</sup>, to quote Benjamin Franklin, “an ounce of prevention is better than a pound of cure”. The pound of cure is expected to generate US\$4.5 billion by 2020. Can and should the eye care industry prevent dry eye through effectively treating blepharitis and eventual meibomian gland loss before our patients are symptomatic? Is dry eye and blepharitis one entity, that is dry eye blepharitis syndrome or DEBS, reflecting, in fact, a single disease process rather than two distinct processes<sup>3</sup>? As primary eye care practitioners, optometrists have the opportunity to play a key role in the prevention, not just the treatment of dry eye disease, by supporting the increasingly strong argument that blepharitis and dry eye should be treated and prevented by early and routine biofilm removal with microblepharoexfoliation and regular and routine eyelid hygiene.

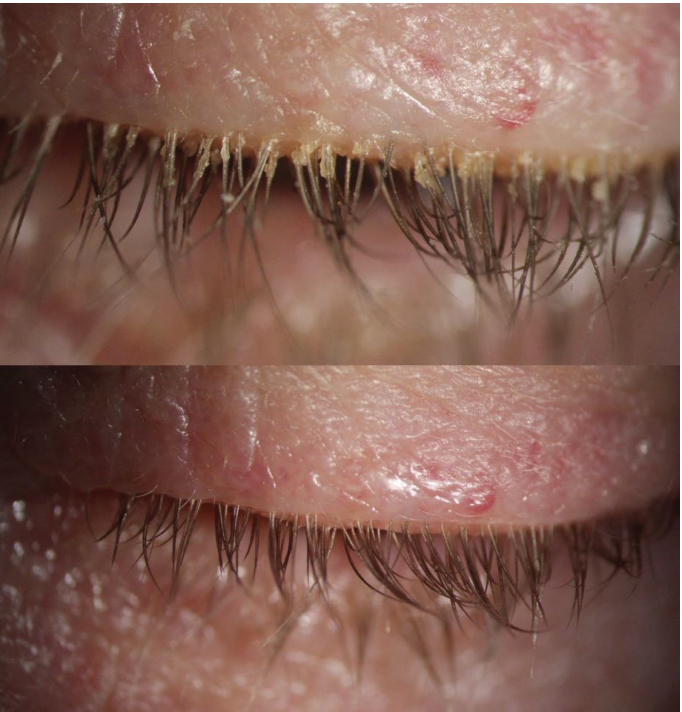

Fig 2. An Eyelid before and after in-office treatment with microblepharoexfoliation

For more on Demodex and dry see Eye on Ophthalmology on p10, and on blepharitis’ treatment see the Manuka honey study story on p10 and the UNSW story on p13.

## References

1. Bernardes, T.F. and A.A. Bonfili, Blepharitis. Seminars in Ophthalmology, 2010. 25(3): p. 79-83.
2. Brothers, K.M., et al., Dexamethasone diffusion across contact lenses is inhibited by Staphylococcus epidermidis biofilms in vitro. Cornea, 2014. 33(10): p. 1083-7.
3. Rynerson, J.M. and H.D. Perry, DEBS – a unification theory for dry eye and blepharitis. Clin Ophthalmol, 2016. 10: p. 2455-2467.
4. Moran, E.M., R. Foley, and F.C. Powell, Demodex and rosacea revisited. Clin Dermatol, 2017. 35(2): p. 195-200.
5. Christersson, L.A., J.J. Zambon, and R.J. Genco, Dental bacterial plaques. Nature and role in periodontal disease. J Clin Periodontol, 1991. 18(6): p. 441-6.
6. Cannady, K. Dry Eye Products Market Expected to Generate \$4.5 Billion by 2020. 2016 [cited 2017 18 July]; Available from: <https://market-scope.com/pressrelease/dry-eye-products-market-expected-to-generate-4-5-billion-by-2020/>.

*\*Lachlan Scott-Hoy is a well-known presenter and owner of Innovative Eye Care in Australia. He has a special interest in orthokeratology and contact lenses and is director of Innovative Contacts, a company which specialises in the design, supply, and advice for fitting RGP contact lenses*

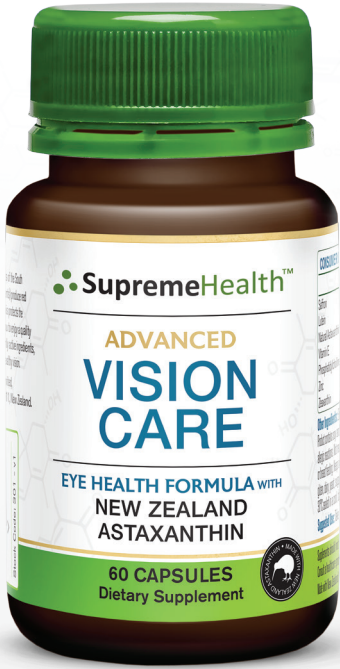## Advanced Vision Care with AstaNZ™ - New Zealand Astaxanthin

### THE WORLD'S MOST POWERFUL ANTIOXIDANT FROM THE FRESH WATERS OF NEW ZEALAND

Supreme Health's Advanced Vision Care formulation combines the power of AstaNZ™ (New Zealand natural Astaxanthin) with Lutein, Zeaxanthin and Saffron to create a comprehensive and powerful carotenoid complex to boost all aspects of eye health and protect the eye, whatever age you are.


Astaxanthin is the only antioxidant, not naturally present in the eye, that can penetrate the retinal-blood barrier and protect every cell of the eye from oxidative stress.

For more information about the product please visit our website – [www.supremehealth.co.nz](http://www.supremehealth.co.nz) or contact us via email – [sales@supremehealth.co.nz](mailto:sales@supremehealth.co.nz)



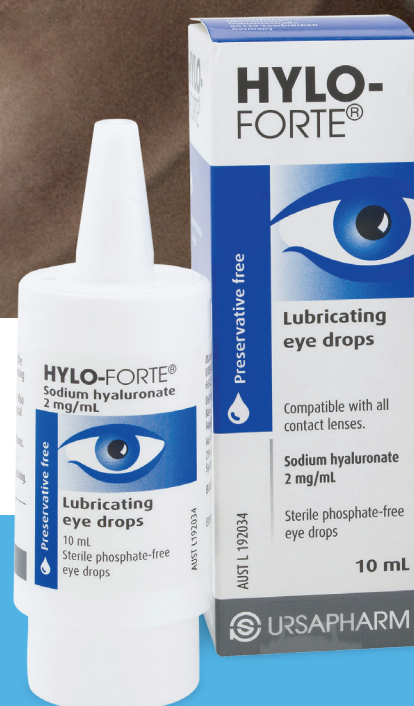**SupremeHealth™**



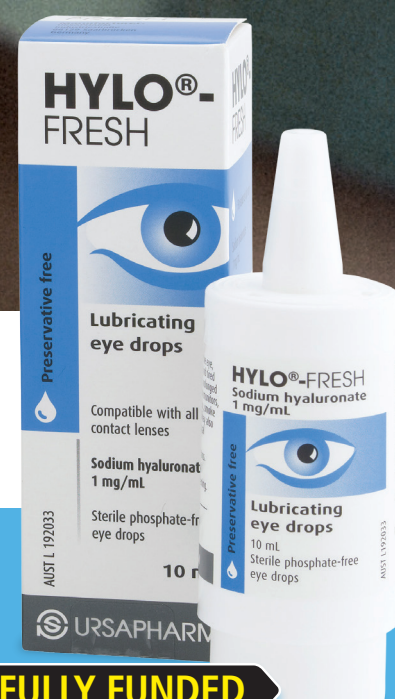

# HYLO® EYE CARE

**Long-lasting lubrication for dry eyes that is preservative-free and completely sterile, delivered through the unique COMOD® multi-dose application system.**



**For severe or chronic dry eye**



**FULLY FUNDED**

*Special authority criteria applies\**

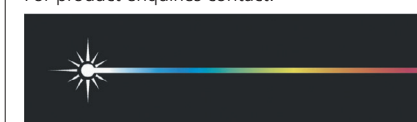
**For mild to moderate dry eye**

## The systematic approach to eye lubrication

*for*  
**Dry Eyes**

- ▶ **Preservative-free and phosphate-free**
- ▶ **Can be used for 6 months after opening**
- ▶ **Compatible with all types of contact lenses**
- ▶ **At least 300 measured drops per pack, or 150 treatments (both eyes)**

For product enquiries contact:



CORNEAL LENS  
CORPORATION N.Z. LTD

*ideas into practice*  
[www.corneal-lens.co.nz](http://www.corneal-lens.co.nz)

\*Special Authority criteria applies only to HYLO®-FRESH – please refer to the New Zealand Pharmaceutical Schedule for details.

HYLO®-FRESH (Sodium hyaluronate 0.1% w/v, 10mL) and HYLO-FORTE® (Sodium hyaluronate 0.2% w/v, 10mL) eye drops are General Sales Medicines to improve the lubrication of the eyes, in eyes that are dry, irritated and tired from external factors. Always read the label and use strictly as directed. If symptoms persist see your healthcare professional. HYLO®-FRESH, HYLO-FORTE® and COMOD® are registered trademarks of URSAPHARM. AFT Pharmaceuticals, Auckland. TAPS 1733HA.



## Health Headlines

Hartley Atkinson M.Pharm, PhD  
Founder & CEO, AFT Pharmaceuticals

0800 423 823  
[www.aftpharm.com](http://www.aftpharm.com)

**NZX**  
**LISTED**

**AFT** *pharmaceuticals*  
*Working to improve your health*



# Dunedin tackles dry eye

BY DR GRAHAM WILSON\*

In conjunction with the University of Auckland’s Ocular Surface team, led by Associate Professor Jennifer Craig, and their international collaborators, dry eye is being investigated as part of the well established Dunedin Study\*. Study members (n=1032) are being asked to answer a dry eye questionnaire and then are assessed with the Oculus Keratograph 5M (from Designs for Vision). The keratograph is fundamentally a corneal topographer, but possesses an advanced software module that permits non-invasive analysis of dry eye disease. Among other features, it measures the height of the tear film, the lipid layer, tear break-up time and bulbar redness, and provides non-invasive infra-red imaging of the meibomian glands. Study members who are being followed throughout their lives are now 45 years old and most of the females are therefore pre-menopausal. We anticipate this study will

provide the Southern hemisphere’s, if not the world’s, first dry eye incidence data at this age, providing valuable baseline data for how dry eye develops with increasing age. Plus, because of the multidisciplinary nature of the Dunedin Study, the association of dry eye with a host of other variables such as smoking, cannabis use, systemic inflammation, medication use, depression, occupation and nutritional status can be examined. The impact of dry eye on quality-of-life can and will also be assessed. One of the over-riding research goals of the Dunedin Study is to examine why we all age so differently, so it will be relevant to assess if dry eye is a biomarker of ageing. Data collection will be complete by mid-2018 and peer-reviewed publications will follow.

*“Dr Graham Wilson is a Gisborne-based ophthalmologist and a principal investigator for all eye-related matters on the long-running, internationally ground-breaking Dunedin Study, a detailed study into human health, development and behaviour, led by the University of Otago, which has been tracking over 1000 people since they were born in 1972 and 1973.*

# Dry eye and diabetes

BY DR STUTI MISRA\*

The World Health Organisation (WHO) Global Burden of Disease Study has predicted a worldwide rise of 366 million people with diabetes by the year 2030<sup>1</sup>. By the end of 2015, about 260,000 self-reported suffering from diabetes in New Zealand, almost 6% of the total population. Evidently, a huge percentage of patients have not yet been diagnosed, particularly those with type 2 diabetes. A recent NZ Ministry of Health report acknowledged twice the prevalence rate in Māori and that this population was also more likely to suffer from extensive complications including retinopathy, renal failure and lower limb amputation. Although diabetic retinopathy is recognised to be a major complication, ocular surface abnormalities including dry eye have been documented to eventuate in long-term visual complications. A general threat to the ocular surface integrity in diabetes has been identified, especially with reduced tear production and reduced tear stability and associated peripheral neuropathy<sup>2</sup>. One of the major contributing factors to the development of dry eye in diabetes is the decreased neural reflexes causing reduced corneal sensitivity and leading to an abnormal ocular surface<sup>3</sup>. Another possible explanation for dry eye in diabetes is dysfunction of the ocular surface secretory glands on account of altered innervation. The meibomian and lacrimal glands are responsible for the secretion of the lipid and aqueous layers of the pre-ocular tear film, respectively. Meibomian glands are innervated by parasympathetic fibres in addition to minimal contribution from sympathetic and sensory neurons<sup>4</sup>. Both sets of glands are believed to be affected in diabetes leading to marked tear film disruption. Patients with diabetes typically complain of dry eye symptoms including grittiness, burning and foreign body sensations. In more severe cases, apparent tolerance to dryness and epitheliopathy can occur as a result of decreased corneal sensitivity associated with the development of diabetic neurotrophic keratopathy<sup>5</sup>. The higher glucose concentration in tears in diabetes that arises from conjunctival vessel leakage, alters the wound-healing capability of the cornea and decreases lacrimation by damaging the microvascular supply to the lacrimal gland<sup>6</sup>. Tear film stability, as measured by the tear break-up time is reduced in diabetes<sup>7</sup> which may occur alongside peripheral neuropathy and poorly controlled disease<sup>3</sup>. The goblet cells, the main source of the tear film mucins that function to protect the cornea and promote a stable tear film, are decreased in diabetes thereby contributing to tear film instability. In addition to its effect on tear

film stability, peripheral neuropathy is also believed to diminish basal tear production in diabetes by disrupting lacrimal gland function<sup>8</sup>. Lower tear production rates, as assessed by Schirmer test, are reported in diabetes<sup>3</sup>. It has also been suggested that diabetic retinopathy and pan-retinal photocoagulation (widely used treatment for retinopathy) may further increase the likelihood of dry eye in diabetic individuals<sup>7</sup>. A number of treatment options are available for diabetic dry eye including topical use of lubricant eye drops, gels, ointments and more recently growth factors. Opioid growth factor, insulin and substance P are some of the many growth factors currently being researched as potential treatment modalities for diabetic dry eye. Substance P is a neuropeptide released from trigeminal sensory nerve endings onto the ocular surface, into conjunctival and corneal tissues, as well as the tear film. Furthermore, substance P is believed to play an important role in wound healing. Markoulli et al recently reported that substance P is expressed at a significantly lower level in the tears of patients with diabetes than in healthy participants<sup>9</sup>. A simple assessment of tears to detect expression of substance P could therefore potentially be used as a bio-marker, alongside non-invasive *in vivo* confocal microscopy of cornea, for monitoring diabetic peripheral neuropathy as an alternative to the painful foot-punch biopsies currently used in clinics.

### References

1. Definition, Diagnosis and Classification of Diabetes Mellitus and its Complications. Report of a WHO Consultation. 1999.
2. Misra SL, Patel DV, McGhee CN, et al. Peripheral neuropathy and tear film dysfunction in type 1 diabetes mellitus. *Journal of diabetes research* 2014;2014:848659.
3. Dogru M, Katakami C, Inoue M. Tear function and ocular surface changes in noninsulin-dependent diabetes mellitus. *Ophthalmology* 2001;108:586-592.
4. Chung CW, Tigges M, Stone RA. Peptidergic innervation of the primate meibomian gland. *Invest Ophth Vis Sci* 1996;37:238-245.
5. Alves Mde C, Carvalheira JB, Modulo CM, Rocha EM. Tear film and ocular surface changes in diabetes mellitus. *Arq Bras Oftalmol* 2008;71:96-103.
6. Kaiserman I, Kaiserman N, Nakar S, Vinker S. Dry eye in diabetic patients. *American Journal of Ophthalmology* 2005;139:498-503.
7. Ozdemir M, Buyukbese MA, Cetinkaya A, Ozdemir G. Risk factors for ocular surface disorders in patients with diabetes mellitus. *Diabetes Res Clin Pract* 2003;59:195-199.
8. Cousen P, Cackett P, Bennett H, Swa K, Dhillon B. Tear production and corneal sensitivity in diabetes. *J Diabetes Complications* 2007;21:371-373.
9. Markoulli M, You J, Kim J, et al. Corneal Nerve Morphology and Tear Film Substance P in Diabetes. *Optometry and vision science : official publication of the American Academy of Optometry* 2017;94:726-731.

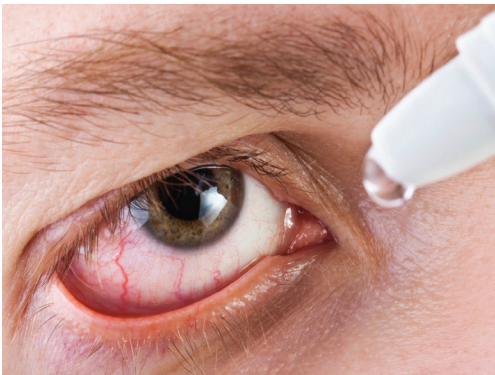### About the author

*“Dr Stuti Misra is a Stevenson Research Fellow in the ophthalmology department at the University of Auckland.*

# Banking on dry eye

BY LESLEY SPRINGALL

The dry eye treatment market is estimated to be growing at more than 6.5% per year and is expected to generate US\$4.5 billion in revenues by 2020 (US\$2.2bn for artificial tears alone). It’s little surprise then that dry eye appears to be fueling a rush of potential new drugs, devices and treatments, with news of study milestones, technology launches, biotech acquisitions and new Food & Drug Administration (FDA) filings hitting inboxes, seemingly every month. Associate Professor Jennifer Craig says new treatments are not just being driven by big pharma’s desire to capitalise on this growing problem, but also the industry’s growing understanding of how and why dry eye disease (DED) develops. “As our understanding of the pathophysiological processes involved in DED improve, there’s certainly been an increased interest in trying to treat DED rather than simply manage symptoms as we’ve been doing until lately.” Globally, the prevalence of DED, with and without symptoms, ranges from 5 to 50%, and up to 75% based on signs alone in some populations, according to the newly-released TFOS DEWS II report (see pX). In population numbers, this relates to between 60 million and 337 million people worldwide, most commonly older people and especially older women, according to other sources. The main approach to treating dry eye to date has been artificial tears, improved diet (omega-3, astaxanthin) and treating the inflammation with topical cyclosporine and corticosteroids. In the prescription drug market, Allergan’s Restasis (cyclosporine ophthalmic emulsion) has dominated the US market for more than 10 years, having been the first dry eye drug to be granted FDA approval in 2002. This product alone, is estimated to have earned Allergan US\$1.05bn in 2015. Other big pharma have been trying in vain to knock Restasis from its perch, but it wasn’t until July last year that the FDA granted approval for a second dry eye drug, Xiidra (lifitegrast) produced by Shire Pharmaceuticals. Xiidra, like Restasis, targets inflammation, but as an integrin antagonist that decreases inflammation on the ocular surface. Meanwhile, a Restasis-like drug, Seciera, was sold by Auvien Therapeutics, a private equity firm based in the US Virgin Islands to India’s Sun Pharma for US\$40 million plus undisclosed milestone payments, in January this year, following the successful publication of phase III trials. Also in the wings, but with an entirely different mode of action, is US-based Lubris’ catchily-named




Capitalising on dry eye is big business

ECF843, a recombinant form of human lubricin, an endogenous glycoprotein that protects tissue surfaces from friction-induced damage. Artificial tear manufacturer Novartis exercised an option, this year, to in-license ECF843 for use outside Europe, after a small phase II study demonstrated immediate relief to sufferers, following application of the product, with no adverse effects. Another company buying its way into the market is Imprimis Pharmaceuticals, which licensed the worldwide rights to a new ophthalmic topical solution and gel technology called Klarity, developed by US-based cataract and refractive surgeon and Imprimis’ board member, Dr Richard Lindstrom. According to the company, this new solution is specifically designed for the treatment of ocular surface pathology in patients with moderate to severe dry eye associated with ophthalmic surgery and contact lens wear. “Over-the-counter topical lubricating drops positioned for mild to moderate dry eye can be helpful, but they do not treat the associated oedema, free radical formation or have an agent like chondroitin sulfate, which can serve as a cell membrane stabiliser. There is clearly a vast and relatively untapped market that could greatly benefit from Klarity’s proprietary formulation and function,” said Dr Lindstrom in a press release. But it’s not just new drugs jostling for a share of the increasingly lucrative worldwide dry eye treatment market. New treatments such as intense pulsed light (IPL) are also coming to the fore with several companies such as French hair removal company E Swin’s E>Eye (distributed by France Medical), Lumenis’ M22, and now the Italian-based Espansione Group’s Eye-Light (distributed by Designs for Vision), all offering dedicated IPL technology for treating meibomian gland dysfunction (MGD). Dr Rolando Toyos, the US-based ophthalmologist and self-professed originator of IPL treatment for DED, who works with both Shire and Lumenis, also revealed results of a study at ARVO this year, showing how red light therapy can help patients self-treat MGD at home. While in August, Johnson & Johnson agreed to acquire MGD treatment device company Tear Science for an undisclosed sum, through its surgical vision operating company, Abbott Medical Optics. Tear Science’s devices including its meibomian gland imaging tools Lipiview, Lipiview II and Lipiscan, and the Lipiflow Thermal Pulsation System which treats evaporative dry eye by liquefying and evacuating obstructions in the glands. Subject to antitrust clearance, the deal is expected to close by the end of the year. Another new treatment making news is Allergan’s True Tear intranasal tear neurostimulator, which was bought by Allergan as part of its acquisition of Oculeve in mid-2015 for US\$125 million plus milestones. This novel treatment approach, which was developed and tested as part of a worldwide study which included Auckland Eye, Eye Institute and the University of Auckland (see story p13), involves a hand-held stimulator and daily disposable tips that are inserted into the nasal cavity to induce tear flow. “True Tear represents a technological breakthrough for eye care professionals as it delivers an effective, non-invasive and drug-free way to temporarily increase tear production,” said David Nicholson, Allergan’s chief R&D officer. True Tear gained FDA approval in the US as a prescription device in April this year. There’s no doubt that these new and as yet unveiled treatment options will offer an improved range of management options for the world’s dry eye sufferers, says A/Prof Craig, but dry eye treatment is “unlikely ever to be easy,” given the complexity of DED and the challenges in diagnosis and treatment. “But beyond the advances we’re seeing in diagnostic and management tools, care will continue to improve as we use the expanding scientific evidence to help us better understand the disease. More accurate classification of patients according to their presenting features allows clinicians to set more realistic expectations for outcomes to the benefit of both clinicians and their patients.” ■



India’s Sun Pharma and Shire’s Xiidra both hope to knock Allergan’s Restasis of its dry eye treatment perch



## List now in the 2018 Optical Information Guide (OIG)

Make sure you’re listed in New Zealand’s only comprehensive guide to all things optical. Contact Janis Ord at [janis@nzoptics.co.nz](mailto:janis@nzoptics.co.nz) and secure your listing.





# Demodex: the mighty mite or pesky parasite?

BY DR ISABELLA CHEUNG\* AND A/PROF JENNIFER CRAIG

*Infestation of the eyelash follicles and meibomian glands with Demodex mites is emerging as a significant cause of blepharitis. This article reviews key aspects of Demodex biology and pathogenesis, as well as the epidemiology, clinical manifestation, diagnosis and treatment of infestation.*

## Demodex biology and epidemiology

Two species of Demodex infest the human eye: *Demodex folliculorum* inhabit the eyelash follicles, while *Demodex brevis* reside in the meibomian glands. These species are therefore capable of causing both anterior and posterior blepharitis, respectively<sup>1</sup>. The larger of the two species, *D. folliculorum* grows up to 0.4mm in length, while *D. brevis* are typically up to 0.2 mm long. As *D. folliculorum* are found close to the opening of the eyelash follicle, frequently with the posterior end of the abdomen protruding and visible, while *D. brevis* are located deep in the meibomian glands, the transmission of *D. folliculorum* is higher and has become recognised as the most common parasitic infestation of the eyelid<sup>2,3</sup>. The reported life span of Demodex is variable, with estimates of 28 and 100 days, however, mite survival is limited outside the human body<sup>4,5</sup>. Transmission occurs via direct contact and transfer of the adult mites, larvae or eggs.

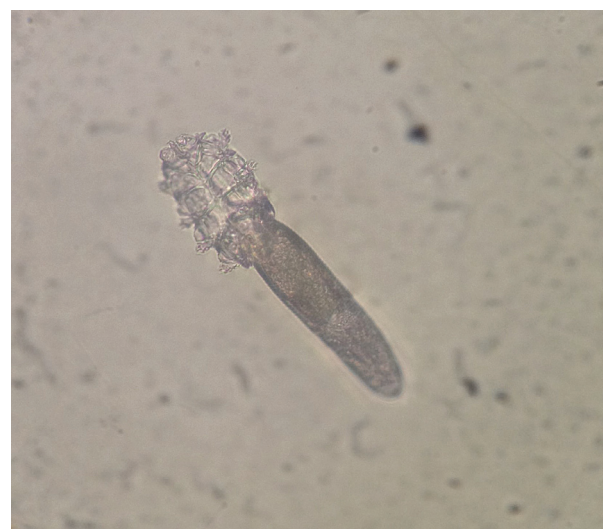

Fig 1. *D. folliculorum* under light microscopy

The prevalence of Demodex infestation rises with age, with reported infestation rates of 13% in individuals 3-15 years of age, 69% in those 31-50 years of age and over 95% in individuals aged 71 years or older<sup>6</sup>. Demodex load in affected individuals also increases with age. Ocular demodicosis is associated with rosacea – the presence of Demodex in the hair follicles and sebaceous glands of the face results in the development of rosacea and it is postulated that these mites spread to the eyelids, leading to periocular infestation<sup>7</sup>.

## Clinical manifestation

The presence of Demodex is strongly associated

with the development and exacerbation of blepharitis, with mites detected in up to 68% of patients with chronic blepharitis<sup>8</sup>. Cylindrical crusting around the eyelashes is considered pathognomonic for demodectic blepharitis<sup>2</sup>. This crusting is believed to comprise of debris from damaged epithelial cells, by-products of meibum digestion and mite excreta. Demodex has been detected in 60% of those with meibomian gland dysfunction (MGD)<sup>9</sup>, the most common form of posterior blepharitis that affects the delivery of lipid to the surface of the tear film.

Characterised by inflammation of the eyelids, blepharitis is one of the most prevalent ocular conditions worldwide, affecting around 47% of patients seen by eye health professionals. In more severe cases, it can result in the development of more serious disorders such as eyelid infection, cyst formation and sight threatening corneal sequelae. Irritated dry eyes, intermittent visual disturbance, and ocular surface and eyelid redness, however, are symptomatic of blepharitis at all levels of severity.

Of note, Demodex is also common in asymptomatic individuals – up to 18% of those affected do not exhibit symptoms – and it is uncertain why the presence of Demodex elicits an adverse reaction in some individuals, while others remain unaffected. It may be that Demodex constitutes part of the normal skin flora, and that immunodeficiency may be associated with the development of symptoms, although this remains to be established<sup>10-12</sup>. Also unclear is the extent to which mite load correlates with symptom severity. Further investigation into factors affecting disease development is clearly needed.

## Pathogenesis

Consumption of the epithelial cells of the eyelash follicle and meibum-producing cells of the meibomian gland, together with blockage of the eyelash follicle and meibomian glands by Demodex may lead to madarosis and trichiasis, as well as insufficient meibum secretion, respectively. The sharp chelicera (appendages such as the mouthparts and claws) of Demodex may also cause epithelial damage, leading to epithelial hyperplasia, hyperkeratosis and crusting. Demodex may also directly and indirectly trigger immune hyperstimulation. Mite excreta as well as chitin, the main component of the Demodex exoskeleton, are antigenic, as are by-products from their digestion of meibum. In addition, Demodex is viewed as a potential vector for bacteria, particularly *Bacillus oleronius*, which further triggers immune responses.

## Diagnosis

As previously mentioned, the observation of cylindrical crusting encircling the eyelashes under slit lamp biomicroscopy may be a convenient

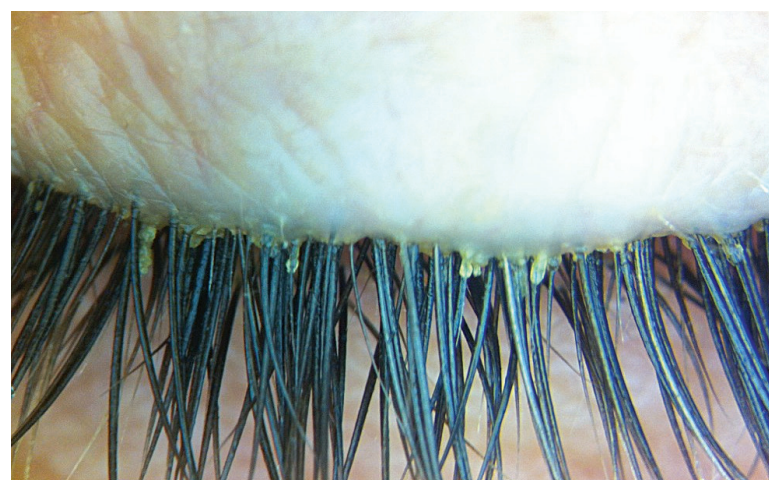


Fig 2. Cylindrical eyelash crusting under slit lamp biomicroscopy is considered pathognomonic of Demodex infestation

clinical indicator of ocular demodicosis<sup>2</sup>. However, the current gold standard diagnostic test remains the examination of epilated eyelashes for the presence of mites, under 250x magnification light microscopy. It has been suggested that targeted epilation of eyelashes with cylindrical crusting and up to 30 seconds rotation of the eyelash within the follicle prior to epilation may increase Demodex yield<sup>2,13</sup>. However, this diagnostic approach is not without challenges; many mites can remain inside the follicle following epilation, mite numbers on each eyelash can vary considerably, and mites may be obscured by crusting and debris. Finally, due to the inaccessibility of Demodex residing deep in the meibomian glands, infestation in cases of posterior demodectic blepharitis remains difficult to diagnose.

The utility of *in vivo* confocal microscopy (IVCM) and polymerase chain reaction (PCR) in the diagnosis of ocular demodicosis are being explored. IVCM can permit visualisation of Demodex inside the eyelash follicle without epilation; its ability to assess mites within the meibomian glands in cases of posterior demodectic blepharitis should also be investigated<sup>14</sup>. In the laboratory, PCR can be used to detect minute quantities of genetic material from Demodex. The Ocular Surface Laboratory at the University of Auckland is currently developing PCR-based and other molecular diagnostic tests in the hope of improving the diagnosis of ocular infestation.

## Treatment

Demodex are susceptible neither to antibiotic therapy nor to conventional blepharitis treatments such as eyelid hygiene, artificial tears and warm compresses. Tea tree oil (TTO) is the current standard treatment for ocular demodicosis to target the causative organism. Extracted from the *Melaleuca alternifolia* tree, TTO has a long history of use for its antiseptic properties. Topical treatment of the eyelid region with TTO decreases Demodex load, ocular surface discomfort, tear film abnormalities and ocular inflammation and improves visual acuity<sup>9</sup>. A regime of 50% TTO weekly (mixed with a bland oil such as almond or macademia oil) followed by cleansing with a 10% TTO solution daily for 4 weeks has been described<sup>15</sup>, as has a regime of 50% TTO weekly combined with TTO shampoo daily for 6 weeks<sup>16</sup>. Ocular surface irritation induced by full strength TTO precludes its use clinically. Lower concentrations of TTO have also shown some benefit<sup>17</sup>. Terpinen-4-ol is the key active component of TTO and exhibits an acaricidal effect on Demodex. Specialised eyelid cleansers, containing TTO and terpinen-4-ol to facilitate eyelid hygiene in the management of transmissible blepharitis, are commercially available. However, their efficacy in managing demodectic blepharitis has not yet been confirmed in the literature. Studies are underway at the Ocular Surface Laboratory to assess and compare levels of terpinen-4-ol in commercial eyelid cleansing preparations and their relative effects on Demodex viability *in vitro*.

As both TTO and acaricides have adverse effects on the ocular surface, the Ocular Surface Laboratory is also currently investigating the efficacy of a topical cyclodextrin-complexed Manuka honey preparation on Demodex viability *in vitro* and on ocular demodicosis *in vivo*.

Less commonly, systemic treatments are prescribed to manage Demodex infestation. Oral ivermectin (used in sheep dip), prescribed alone or in combination with metronidazole, has been shown to reduce Demodex load and the clinical signs and symptoms of infestation, with a greater improvement demonstrated by the combination therapy<sup>18</sup>. Given Demodex's association with blepharitis, is prevention better than cure?

Australian optometrist and CL specialist, Lachlan Scott-Hoy tackles this question on p14. ■

## References

- Liu J, Sheha H, Tseng SCG. Pathogenic role of Demodex mites in blepharitis. Current opinion in allergy and clinical immunology. 2010;10(5):505-10.
- Gao Y-Y, Di Pascuale MA, Li W, Liu DT-S, Baradaran-Rafii A, Elizondo A, et al. High prevalence of Demodex in eyelashes with cylindrical dandruff. Investigative ophthalmology & visual science. 2005;46(9):3089-94.
- Basta-Juzbašić A, Subić JSK, Ljubojević S. Demodex folliculorum in development of dermatitis rosaceaformis steroidica and rosacea-related diseases. Clinics in Dermatology. 2002;20(2):135-40.
- Spickett SG. Studies on Demodex folliculorum Simon (1842). I. Life history. Parasitology. 2009;51(1-2):181-92.
- English FP, Nutting WB. "Feeding characteristics in demodectic mites of the eyelid". Australian Journal of Ophthalmology. 1981;9(4):311-3.
- Czepita D, Kuźna-Grygiel W, Kosik-Bogacka D. Investigations on the occurrence as well as the role of Demodex folliculorum and Demodex brevis in the pathogenesis of blepharitis. Klinika oczna. 2005;107(1-3):80-2.
- Li J, O'Reilly N, Sheha H, Katz R, Raju VK, Kavanagh K, et al. Correlation between Ocular Demodex Infestation and Serum Immunoreactivity to Bacillus Proteins in Patients with Facial Rosacea. Ophthalmology. 2010;117(5):870-7.e1.
- Humiczewska M. Demodex folliculorum and Demodex brevis (Acarida) as the factors of chronic marginal blepharitis. Wiadomości parazytologiczne. 1991;37(1):127.
- Gao Y-Y, Di Pascuale MA, Elizondo A, Tseng SCG. Clinical Treatment of Ocular Demodicosis by Lid Scrub With Tea Tree Oil. Cornea. 2007;26(2):136-43.
- Seyhan M, Karıncaoglu Y, Bayram N, Aycan O, Kuku I. Density of Demodex folliculorum in haematological malignancies. Journal of international medical research. 2004;32(4):411-5.
- Jansen T, Kastner U, Kreuter A, Altmeyer P. Rosacea-like demodicidosis associated with acquired immunodeficiency syndrome. British Journal of Dermatology. 2001;144(1):139-42.
- Antille C, Saurat J, Lübke J. Induction of rosaceaform dermatitis during treatment of facial inflammatory dermatoses with tacrolimus ointment. Archives of Dermatology. 2004;140(4):457-60.
- Mastrota KM. Method to identify Demodex in the eyelash follicle without epilation. Optometry & Vision Science. 2013;90(6):e172-4.
- Randon M, Liang H, El Hamdaoui M, Tahiri R, Batellier L, Denoyer A, et al. In vivo confocal microscopy as a novel and reliable tool for the diagnosis of Demodex eyelid infestation. British Journal of Ophthalmology. 2014;bjophthalmol-2014-305671.
- Koo H, Kim TH, Kim KW, Wee SW, Chun YS, Kim JC. Ocular Surface Discomfort and Demodex: Effect of Tea Tree Oil Eyelid Scrub in Demodex Blepharitis. J Korean Med Sci. 2012;27(12):1574-9.
- Kheirkhah A, Casas V, Li W, Raju VK, Tseng SC. Corneal manifestations of ocular Demodex infestation. American journal of ophthalmology. 2007;143(5):743-9. e1.
- Nicholls SG, Oakley CL, Tan A, Vote BJ. Demodex species in human ocular disease: new clinicopathological aspects. International Ophthalmology. 2017;37(1):303-12.
- Salem DA-B, El-shazly A, Nabih N, El-Bayoumy Y, Saleh S. Evaluation of the efficacy of oral ivermectin in comparison with ivermectin-metronidazole combined therapy in the treatment of ocular and skin lesions of Demodex folliculorum. International Journal of Infectious Diseases. 2013;17(5):e343-e7.




Dr Isabella Cheung

## About the author

\*Dr Isabella Cheung is a research fellow in the Department of Ophthalmology at the University of Auckland.

This test could save your sight



0800 622 852 mdnz.org.nz

